

Lower Cervical Intramuscular Bupivacaine Injections — Another Treatment Option for Headaches

a report by

Gary A Mellick, DO, DAAPM and **Larry B Mellick, MS, MD, FACEP, FAAP**

*President and CEO, American Pain Specialists, and Professor, Department of Emergency Medicine,
Medical College of Georgia*

The lifetime prevalence of headache is over 90%. The reported prevalence of migraine headaches is 18.2% among females and 6.5% among males. Headache is a common complaint for which patients seek relief in the emergency department (ED) setting. The management of headaches in US EDs includes an armamentarium of medications delivered by the oral, subcutaneous, intramuscular, or intravenous routes. It has been characterized as a “broad pharmacopeia of medications” with opioids commonly administered, especially meperidine.

In this article a new anesthetic injection technique is presented, which appears to be an effective therapeutic option for the entire spectrum of International Headache Society (IHS) classification headaches. This technically simple procedure is rapidly accomplished, and results are typically robust, occurring in five to 10 minutes. Patient length of stay in the ED appears to be shortened and other more time-consuming treatment interventions are avoided. Based on the rapid resolution of headache pain and other trigeminovascular system-related signs and symptoms following these injections, connections to the trigeminal system appear to be involved. Three patients illustrative of the therapeutic response to the lower cervical injection with bupivacaine are presented.

Case One (Migraine Without Aura)

This 33-year-old Caucasian female presented to the ED for pain relief from her usual migraine headache that began two days earlier. She described light sensitivity, nausea and vomiting. Her usual abortive medications were attempted without relief. The headache began on the left but became bilateral and was 10/10 in severity. The patient denied any other medical problems. She was treated with injections of 1.5ml of bupivacaine bilateral to the spinous process of the seventh cervical vertebra. The patient experienced relief of her headache to 1/10 in less than five minutes. She also described complete relief of her photophobia and nausea. Subsequently, the patient reported that she did not have her usual headache postdrome that typically would affect her during the following 24 hours.

Nine days later this patient returned to the ED for

treatment of a migraine headache that was initiated by the “smell of strong cologne”. Again, photophobia and nausea accompanied the headache. The patient again received bilateral intramuscular injections of 1.5ml of 0.5% bupivacaine at the level of C-7 spinous process. The time from the anesthetic injections to complete headache relief was exactly six minutes. The patient had two subsequent visits to the ED for similar migraine headaches over several months and responded consistently to the cervical injection therapy.

Case Two (Infrequent Episodic Tension-type Headache)


This 43-year-old black female complained of a constant frontal, unilateral headache for three days prior to arrival in the ED. Similar headaches would occur “every now and then”. The patient described the headache as a tight band about her head. She denied an aura, numbness, phonophobia, photophobia, nausea, or vomiting. Even though she reported feeling “congested”, there was no clinical evidence of sinusitis. The headache was 6/10 in severity. Bilateral lower cervical injection with bupivacaine resulted in complete resolution (0/10) of the headache in approximately five minutes. In follow-up, the patient confirmed that she remained headache-free after leaving the ED, and that she was able to return immediately to her daily activities.

Case Three (Acute Post-traumatic Headache)

A 22-year-old white male sustained a head injury and orofacial trauma after colliding with a friend while roller blade skating. A brief loss of consciousness occurred. Additionally, there was avulsion and subsequent reimplantation of the right maxillary central incisor as well as extrusive luxation of the mandibular central incisors. Since the accident the patient had experienced on-going severe right maxillary dental pain with hypersensitivity to cold water and light touch. He also experienced significant dental and gingival pain in the luxated but stabilized teeth. His pain was unresponsive to hydrocodone with acetaminophen or oxycodone with acetaminophen. In



Gary A Mellick, DO, DAAPM



Larry B Mellick, MS, MD, FACEP, FAAP

Gary A Mellick, DO, DAAPM, is President and CEO of American Pain Specialists Inc., Grafton, Ohio. He is Director of the Pain Consultation Clinic, Chalmers P Wyllie Veterans Clinic, US Department Of Veterans Affairs, Columbus, Ohio. He was previously Flight Commander/Lt.Col., US Air Force, 1999 to 2003, Director of the Human Performance Laboratory, US Army Health Clinic, Pentagon, Washington DC, 1985 to 1988, Chief of Aviation Medicine, Troop Medical Clinic, 1984 to 1985, and Chief of the Family Practice section, US Army Academy of Health Sciences, 1981 to 1984.

Larry B Mellick, MS, MD, FAAP, FACEP, is Professor in the Department of Emergency Medicine, Medical College of Georgia and currently works as a physician consultant. He was Chairman, Department of Emergency Medicine, Medical College of Georgia, 1996 to 2003, Chief of Service and Chairman, Department of Emergency Medicine, Loma Linda University Medical Center, 1993 to 1996, and Director of Pediatric Emergency Medicine for both institutions.

addition, the patient reported a constant, throbbing, posterior headache rated at 7–10/10 in severity. A C-7 paraspinal intramuscular bupivacaine injection was performed bilaterally. Not only was the patient's headache relieved, his dental pain was reduced to 1/10 in severity. Subsequent to the injection, the patient was able to bite down, drink tap water, and run cold water over his previously painful teeth. In follow-up, the patient reported that his dental pain remained diminished and that the headache had not returned.

Discussion

Even though this procedure appears to suppress an activated trigeminovascular system through an interface with the trigeminocervical complex, it is not clear why this injection is effective in relieving headache pain as well as many of the associated signs and symptoms. This pain relief may be related to the convergence of the trigeminal nerve with sensory fibers from the upper cervical roots at the trigeminal nucleus caudalis. Clinical clues also suggest that other mechanisms or nervous system structures may be involved.

publications suggest that brainstem nuclei and periaqueductal gray (PAG) matter are key in the pathophysiology of migraine. Furthermore, it is well recognized that descending modulation from supraspinal sites influences spinal nociceptive input and that endogenous descending pain modulation can be triggered by aversive environmental stimuli, such as stress, illness, or pain. The potential anatomical substrates for central descending inhibition include the thalamus, PAG, rostral ventromedial medulla (RVM), locus coeruleus (LC) as well as other brainstem locations. The PAG is a major nociception integration site and a key pathway of central pain modulation that contains a high amount of opioid receptors and peptides. Much of the output from the PAG projects to the rostral ventromedial medulla (RVM), which in turn projects largely to the dorsal horn of the spinal cord. Activation of the RVM electrically or chemically produces effects similar to PAG activation. The resulting inhibition of nociceptive afferent spinothalamic tract neurons is believed to involve descending cholinergic and monoaminergic systems as well as activation of intrinsic glycinergic and gamma-aminobutyric acid (GABA)ergic dorsal horn circuitry. The RVM is a major relay between the PAG and the

The management of headaches in US emergency departments includes an armamentarium of medications delivered by the oral, subcutaneous, intramuscular, or intravenous routes.

The trigeminal nuclear complex has components in the midbrain, pons, and medulla, and even extends down into the upper cervical segments of the spinal cord. The trigeminal nerve provides sensory innervation to the face as far back as the angle of the jaw and anterior ear. Cervical innervation including C1, C2, and C3 play a prominent role in providing feeling to the head and upper cervical levels of the neck. The descending spinal nucleus of the trigeminal complex is a pain-conducting nucleus from the ipsilateral face. Somatic sensation (pain, touch, temperature) fibers of cranial nerves VII, IX, and X, which innervate the tympanic membrane, external ear canal, and skin of the outer ear, terminate in the spinal trigeminal nucleus and tract in the upper cervical spine as far as C4 to blend with the substantia gelatinosa of the cervical cord. Convergence of these various elements and others on second-order neurons of the trigeminocervical complex appear to be an important anatomical clue to understanding the therapeutic mechanism of the lower cervical bupivacaine injections.

Finally, various lines of evidence identified in recent

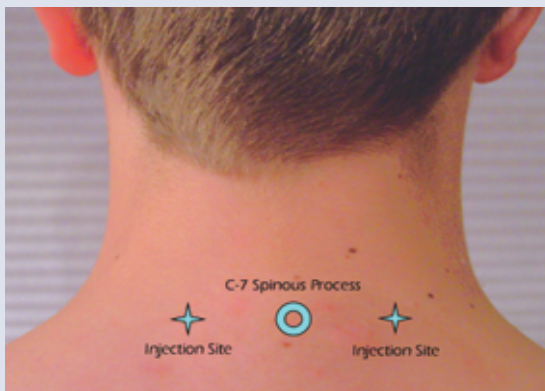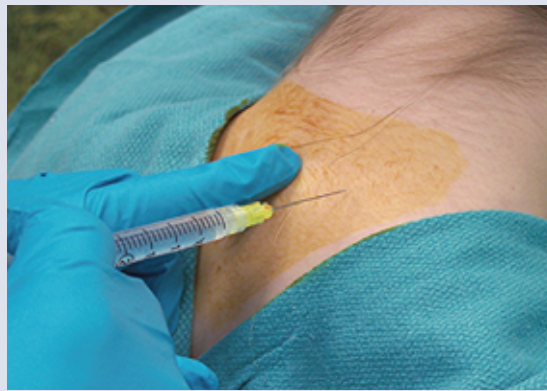spinal cord and has two types of neurons – ‘on-cells’ and ‘off-cells’, which are believed to modulate nociceptive input from the spinal cord dorsal horn neurons and the trigeminal nucleus caudalis. Increased activity of the off-cells in the brain stem's modulatory system is capable of producing a strong antinociceptive response. Both types project to lamina I, II, and V of the dorsal horn and are activated by stimulation of the PAG.

Whatever the mechanism of pain relief, the apparent ‘soft reboot’ process is robust enough to bring about complete headache resolution along with relief of all associated signs and symptoms within minutes. This rapid and complete headache resolution, as well as centrally generated associated signs and symptoms, strongly suggests that the bupivacaine injection is directly affecting elements of the peripheral and central nervous system critical to headache generation and maintenance.

There is evidence that other cervical dorsal root anesthetic injections successfully relieve headaches. Third occipital nerve blocks, injections of lateral atlanto-axial

Procedure Description

After preparation of a sterile field by swabbing with an antiseptic solution over the lower cervical and upper thoracic dorsal spine, 1 to 1 1/2 ml of 0.5% bupivacaine HCl is injected into each location using an 1 1/2 inch 25 gauge needle. The needle is inserted 1 to 1.5 inches into the paraspinous musculature 2 to 3 cm bilateral to the spinous process of the seventh cervical vertebra (see *Figure 1*). The patient is injected while seated, avoiding excessive cervical flexion to prevent injection discomfort due to increased muscle tension. The needle is inserted perpendicular to the transverse plane of the lower dorsal neck and parallel to the examination table (see *Figure 2*). As it passes through muscle and fascia, a slight resistance is noted. The needle is further advanced until unequivocally inserted into cervical muscles. The bupivacaine is injected slowly in each location over one to two minutes in order to minimize discomfort to the patient.

Figure 1**Figure 2**

joints (C1-C2 origin of pain), C2 root ganglion block therapy and methylprednisolone injection near the greater and lesser occipital nerves are documented to relieve headaches.

patients are free of any medication-related side effects or neurologic residua associated with their migraine headaches. This allows patients to resume their daily activities without interruption.

... the lower cervical paraspinous intramuscular injection with bupivacaine appears to be another useful adjunct for the management of headache pain in the ED setting.

Observed or reported complications of this procedure have been muscle soreness at the lower cervical injection site and vasodepressor-related pre-syncope. Other potential complications include a pneumothorax secondary to a needle inadvertently angled downward toward the apex of a lung or an infection caused by the injection.

There are a number of potential benefits associated with this therapeutic technique. The authors feel that the actual costs of bupivacaine and equipment for the intramuscular injection are small when compared with many of the therapeutic interventions currently in use in the ED setting. Additionally, the majority of

In conclusion, the lower cervical paraspinous intramuscular injection with bupivacaine appears to be another useful adjunct for the management of headache pain in the ED setting. Additionally, it seems likely that a greater understanding of the physiology behind the pain relief associated with this injection technique will provide a better understanding of the genesis and pathophysiology of migraine and other IHS headache classifications. ■

A version of this article containing references can be found in the Reference Section on the website supporting this business briefing (www.touchbriefings.com).